

# Hypopigmentation secondary to hair removal by quality-switched 1064-nm neodymium-doped yttrium aluminum garnet: A case series

Haya Al-Orainni<sup>1</sup>, Yasser A Ghobara<sup>2</sup>, Ahmed Al-Issa<sup>2</sup>

<sup>1</sup>College of Medicine, King Saud bin Abdulaziz University for Health Sciences, Riyadh, Saudi Arabia, <sup>2</sup>Derma Clinic, Riyadh, Saudi Arabia

Correspondence to: Haya Al-Orainni, E-mail: Hayaorainni90@gmail.com

Received: January 22, 2017; Accepted: February 07, 2017

## ABSTRACT

The quality-switched 1064-nm neodymium-doped yttrium aluminum garnet (QS 1064-nm Nd:YAG) laser is widely used to treat many skin conditions. Originally, it was used for the treatment of pigmented lesions such as nevus of Ota and tattoo removal. Furthermore, it is widely used in skin rejuvenation and melasma treatment. In daily practice in Saudi Arabia and the Middle East, it is commonly used for hair removal because of its good efficacy and safety profile. According to the advances in the use of QS 1064-nm Nd:YAG, more complications are seen. Hypopigmentation has been reported in multiple case reports as one of the complications after tattoo removal, melasma treatment, and skin rejuvenation. In this case series, we are presenting four cases of hypopigmentation secondary to hair removal by QS 1064-nm Nd:YAG. Three cases were facial hypopigmentation, and one was in the arms. In conclusion, there are no identified risk factors and no standardized measures to avoid this undesired complication.

**KEY WORDS:** Laser; Hair Removal; Hypopigmentation

## INTRODUCTION

The quality-switched 1064-nm neodymium-doped yttrium aluminum garnet (QS 1064-nm Nd:YAG) laser is widely used to treat many skin conditions. Originally, it was used for the treatment of pigmented lesions such as nevus of Ota and tattoo removal.<sup>[1]</sup> In daily practice, it is commonly used for hair removal in Saudi Arabia and the Middle East because of its good efficacy and safety profile.

In general, QS lasers depend on the principle of selective photothermolysis and also produce an additional photoacoustic (photomechanical) effect, producing shock waves that cause an explosion of the target.<sup>[2]</sup> Very high energy is delivered in a very short period (5-100 ns), which leads

to rapid thermal expansion. This produces shock waves that rupture the targeted pigment particles.<sup>[3]</sup> Then, phagocytosis of the pigment by macrophages occurs. The ruptured small fragments are directed by tissue macrophages to the regional lymph nodes.<sup>[4]</sup>


According to the advances in the use of QS 1064-nm Nd:YAG, more complications are seen. Hypopigmentation has been reported as one of the complications.<sup>[1]</sup> This is a devastating complaint about women who undergo this laser treatment for hair removal only.

In these case series, we are presenting four cases of hypopigmentation secondary to hair removal by QS 1064-nm Nd:YAG.

## CASE REPORTS

### Case 1

The first case is a 45-year-old Saudi female, not known to have any medical disease and with no family history of vitiligo. She presented to the dermatology clinic complaining

Access this article online	
Website: <a href="http://www.ijmsph.com">http://www.ijmsph.com</a>	Quick Response code
DOI: 10.5455/ijmsph.2017.0101607022017	

International Journal of Medical Science and Public Health Online 2017. © 2017 Haya Al-Orainni et al. This is an Open Access article distributed under the terms of the Creative Commons Attribution 4.0 International License (<http://creativecommons.org/licenses/by/4.0/>), allowing third parties to copy and redistribute the material in any medium or format and to remix, transform, and build upon the material for any purpose, even commercially, provided the original work is properly cited and states its license.

of hypopigmentation after hair removal by QS 1064-nm Nd:YAG. She received approximately 12 laser sessions within 1 year for facial hair removal. She started noticing the hypopigmented macules after the 6<sup>th</sup> session, in addition, she noticed an increase in size and number of the lesions over a short period. On examination, there were multiple hypopigmented macules involving forehead and cheeks. They showed accentuation on wood's lamp examination. She was treated with tacrolimus 0.03% ointment once daily for 9 weeks with mild improvement before starting on excimer laser sessions.

### Case 2

A 36-year-old Emirati female, known to have hypothyroidism on thyroxin 75 mg/day, presented to the dermatology clinic with hypopigmentation in the face secondary to facial hair removal by QS 1064-nm Nd:YAG. She received 18 sessions for 3 years. She started noticing the hypopigmented patches after the 19<sup>th</sup> session, also lesions increased in both size and number gradually. On examination, she had multiple hypopigmented macules over the forehead and cheeks. Under wood's lamp, there was accentuation of the lesions. She was treated with tacrolimus 0.03% ointment once daily for 9 weeks and she will start narrow-band ultraviolet B (NB-UVB) soon.

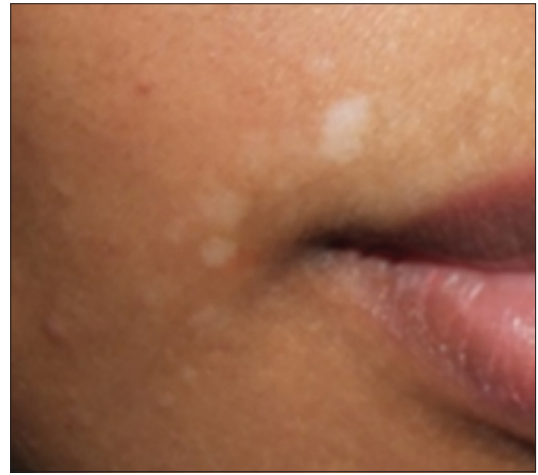### Case 3

A 22-year-old Saudi female, presented with hypopigmented macules over the face after the tenth session of QS 1064-nm Nd:YAG for hair removal within 1 year duration (Figure 1). She had no personal or family history of vitiligo. On examination, there were hypopigmented macules involving forehead and cheeks. Accentuation was observed under wood's lamp. She started tacrolimus 0.1% for 6 months with mild improvement.

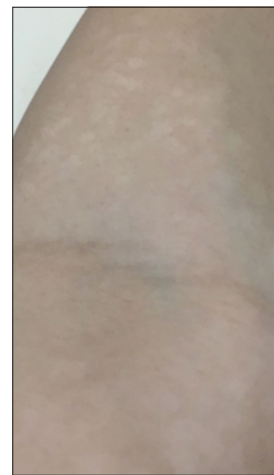### Case 4

A 37-year-old Saudi female, complained of multiple hypopigmented macules over the arms after the second session of QS 1064-nm Nd:YAG for hair removal in a duration of 2 months (Figure 2). She had been diagnosed with polycystic ovary and metformin hydrochloride 500 mg daily was prescribed. She had no personal or family history of vitiligo. On examination, there were hypopigmented macules involving both arms. Accentuation was observed under wood's lamp. She was not started on any treatment yet for the hypopigmented macules.

In the all four cases, the QS 1064-nm Nd:YAG hair removal sessions were performed in another clinic, and hence the parameters are not available.



**Figure 1:** Hypopigmented macules after the tenth session of quality-switched 1064-nm neodymium-doped yttrium aluminum garnet for hair removal within 1 year duration



**Figure 2:** Hypopigmented macules over the arms after the second session of quality-switched 1064-nm neodymium-doped yttrium aluminum garnet for hair removal in a duration of 2 months

## DISCUSSION

QS 1064-nm Nd:YAG is a relatively safe and effective way in hair removal that is commonly used in Saudi Arabia. Goldberg and Samady evaluated the effectiveness of QS 1064-nm Nd:YAG in hair removal, and showed a good efficacy with an average of 59% reduction of hair within 90 days.<sup>[5]</sup> Another study was carried out to compare the safety profile of long-pulsed ruby, long-pulsed alexandrite, and QS 1064-nm Nd:YAG lasers used for hair removal. Transient erythema and perifollicular edema were found in all the three modalities, hypopigmentation was associated with QS 1064-nm Nd:YAG laser in less than 1% compared to 18% and 17% in ruby and alexandrite lasers, respectively.<sup>[6]</sup> Hypopigmentation was also found as a complication of QS 1064-nm Nd:YAG when it was used for melasma and skin rejuvenation.<sup>[1,7]</sup> However, there were no reported cases of hypopigmentation induced by QS 1064-nm Nd:YAG used for hair removal.

Wong *et al.* reported 3 cases of hypopigmentation induced by QS 1064-nm Nd:YAG used for melasma treatment. Two females received weekly sessions for around 1 year before the development of hypopigmentation. The third one noticed it 3 months after the laser treatment. None of these women had personal or family history of vitiligo.<sup>[1]</sup> Another case series reported 14 patients who received QS 1064-nm Nd:YAG laser therapy for skin rejuvenation or melasma and developed hypopigmentation. Laser sessions ranged between 6 and 50 sessions. All patients underwent examination by wood's lamp and depigmentation was confirmed.<sup>[7]</sup> Similarly, patients in our case study did not have a personal or family history of vitiligo. However, the exposure was less with the ladies receiving monthly sessions for approximately 1 year before the development of hypopigmentation, and laser treatment was terminated immediately. On examination of the first three patients, there were hypopigmented macules over the face, especially the cheeks. However, the fourth patient developed hypopigmentation arms. Confirmation was made by wood's lamp and it showed accentuation. Evidently, the hypopigmentation occurrence is not related to the number of session or the reason for laser treatment.

The exact pathophysiology of QS 1064-nm Nd:YAG induced hypopigmentation is not fully understood. However, several authors suggest that there is phototoxicity and cellular destruction of melanocytes (melanocytes photo-damage) occurring due to QS 1064-nm Nd:YAG laser.<sup>[7]</sup> In the case report by Wong *et al.*, a biopsy was taken from one of the patients and it showed that the number of melanocytes in the depigmented lesions was fewer than the patient's normal skin and dendritic processes were decreased.<sup>[1]</sup> On the other hand, the histopathology in two cases reported by Jang *et al.* showed that QS 1064 Nd:YAG laser destroyed melanosome pigments with no change in the melanocytes number.<sup>[8]</sup> Therefore, it was not clear whether the number or the function of melanocyte was affected. Unfortunately, in our three cases, we could not take a biopsy from the patients.

In the first three cases, we presented, tacrolimus 0.1% or 0.03% was prescribed for 9-24 weeks with minimal improvement, so decision was made to treat them with NB-UVB or excimer laser. In a case series by Chan *et al.*, 5 patients out of 14 achieved re-pigmentation after weekly sessions of NB-UVB.<sup>[7]</sup> Moreover, promising results were found with another treatment modality which was used in a 58 year old Korean female where she presented with dyspigmentation after QS 1064-nm Nd:YAG laser treatment for melasma. Excimer laser was used once every 2 weeks and improvement was noticed after 15 sessions. The main advantage of excimer laser is that it has a similar effect as NB-UVB, and also sparing of the non-affected skin.<sup>[9]</sup>

## CONCLUSION

In Saudi Arabia, QS 1064-nm Nd:YAG is widely used for hair removal. Accordingly, more cases of hypopigmentation are seen. Practitioners and patients should be cautious and advised to stop laser treatment on appearance of this undesired complication. Until now, there are no identified risk factors and no standardized measures to avoid it. Further large-scaled studies should be carried out to evaluate the possible occurrence of hypopigmentation secondary to hair removal by QS 1064-nm Nd:YAG.

## REFERENCES

1. Wong Y, Lee SS, Goh CL. Hypopigmentation induced by frequent low-fluence, large-spot-size QS Nd:YAG laser treatments. *Ann Dermatol.* 2015;27(6):751-5.
2. Barua S. Laser-tissue interaction in tattoo removal by q-switched lasers. *J Cutan Aesthet Surg.* 2015;8(1):5-8.
3. Parrish JA. Dohi memorial lecture. Laser medicine and laser dermatology. *J Dermatol.* 1990;17(10):587-94.
4. Aurangabadkar S. Lasers for pigmented lesions and tattoos. In: Venkataram AI, editor. *Textbook on Cutaneous and Aesthetic Surgery.* New Delhi: Jaypee Brothers Medical Publishers (P) Ltd.; 2012. p. 797-813.
5. Goldberg DJ, Samady JA. Evaluation of a long-pulse Q-switched Nd:YAG laser for hair removal. *Dermatol Surg.* 2000;26(2):109-13.
6. Nanni CA, Alster TS. Laser-assisted hair removal: Side effects of Q-switched Nd:YAG, long-pulsed ruby, and alexandrite lasers. *J Am Acad Dermatol.* 1999;41(2):165-71.
7. Chan NP, Ho SG, Shek SY, Yeung CK, Chan HH. A case series of facial depigmentation associated with low fluence Q-switched 1,064-nm Nd:YAG laser for skin rejuvenation and melasma. *Lasers Surg Med.* 2010;42(8):712-9.
8. Jang Y, Park J, Park Y, Kang H. Changes in melanin and melanocytes in mottled hypopigmentation after low-fluence 1,064-nm Q-switched Nd:YAG laser treatment for melasma. *Ann Dermatol.* 2015;27(3):340.
9. Kim H, Jung H, Kim H, Lee J, Park Y. Letter: Punctate leucoderma after low-fluence 1,064-nm quality-switched neodymium-doped yttrium aluminum garnet laser therapy successfully managed using a 308-nm excimer laser. *Dermatol Surg.* 2012;38(5):821-3.

**How to cite this article:** Al-Orainni H, Ghobara YA, Al-Issa A. Hypopigmentation secondary to hair removal by quality-switched 1064-nm neodymium-doped yttrium aluminum garnet: A case series. *Int J Med Sci Public Health* 2017;6(6):1119-1121.

**Source of Support:** Nil, **Conflict of Interest:** None declared.